

Bone Marrow Aspiration

Surgical Technique

Stuart D. Miller, M.D.
Department of Orthopaedic
Surgery
Medstar Union Memorial
Hospital
Baltimore, Maryland

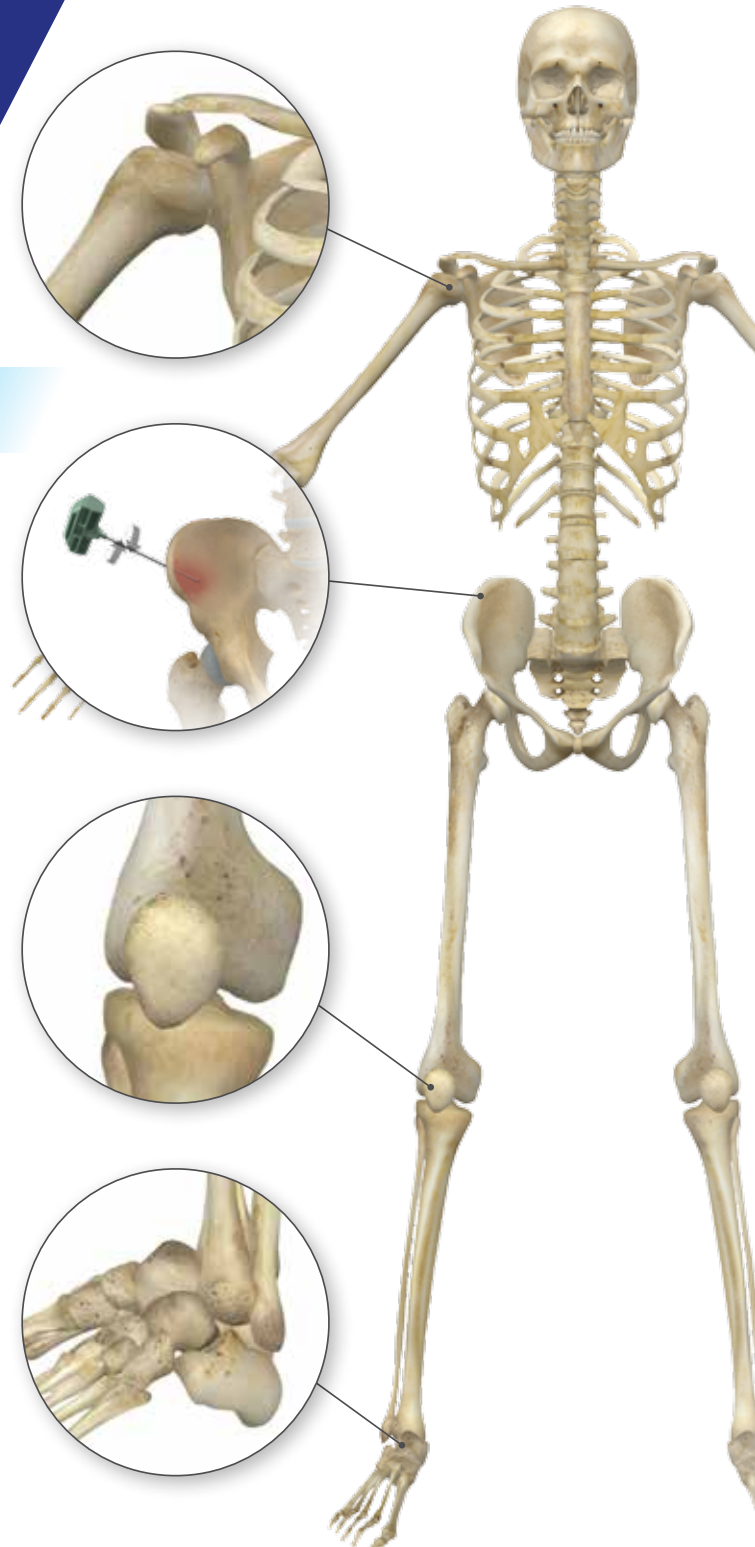


Table of Contents

- Introduction** 2
- Preparation** 3
- Bone Marrow Aspiration Techniques** 5
 - Anterior Iliac Crest 5
 - Posterior Iliac Crest 7
 - Calcaneus 8
 - Distal Tibia 8
 - Proximal Tibia 9
 - Proximal Humerus 9
- Appendix A – Bone Grafting Applications** 10
 - Foot and Ankle 10
 - Spine 11
 - Lower Extremity 12
 - Revision Hip Reconstruction 13
 - Other 14
- Appendix B – Product Catalog Numbers** 15
- Appendix C – Contraindications for Bone Marrow Harvesting** 17
- References** 18

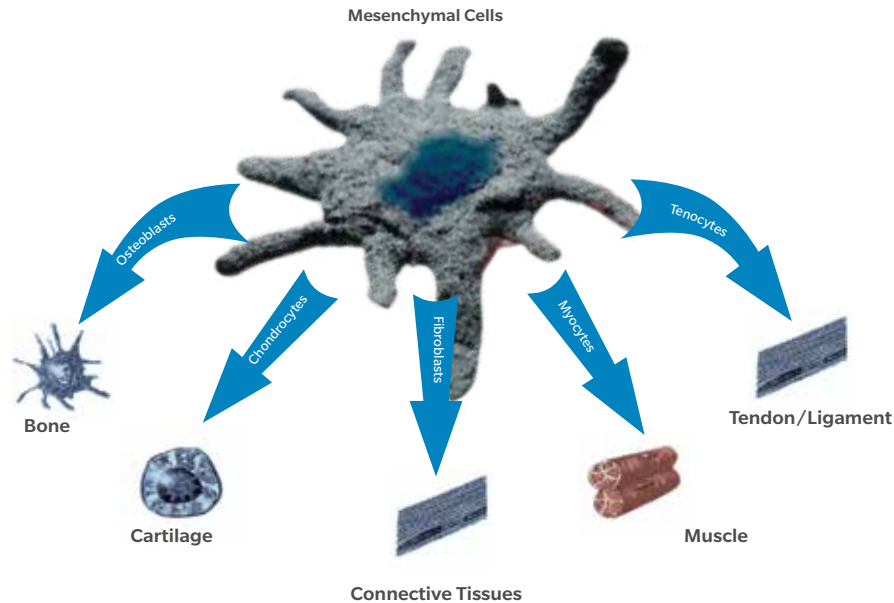


Figure 1

MSCs differentiate into osteoprogenitor cells, and osteoprogenitors differentiate into osteoblasts.

Introduction

Since bone marrow contains a number of bone growth factors as well as stem cells, it can be utilized for many orthopedic procedures.¹⁻⁵ Often, bone marrow is aspirated to utilize the growth factors and cells for tissue repair applications including bone remodeling. Adult mesenchymal stem cells (MSCs) differentiate into osteoprogenitor cells, which in turn differentiate into mature bone-forming cells, called osteoblasts (Figure 1). Bone marrow aspirate (BMA) is a rich source of MSCs and osteoprogenitor cells in the body.⁶⁻⁷ Due to advances in technology, the process of harvesting bone marrow and utilizing it intraoperatively is easier and more routine in many centers.

Bone marrow can be harvested from a variety of anatomic sites during surgery with minimal morbidity. Locations include the iliac crest, vertebral body, calcaneus, proximal or distal tibia, distal femur, and proximal humerus. However, the number of MSCs can vary significantly between locations. In orthopedics, bone marrow aspirate is commonly used in the preparation of allograft bone for implantation.²

By using bone marrow aspirate, osteogenic capacities are added to an allograft bone.¹ Cancellous bone chips as well as bone blocks may be soaked for several minutes in BMA prior to implantation. The recipient site should be irrigated prior to graft placement, while later irrigation should be limited to prevent “washing out” of the bone marrow from the graft.

Several studies show bone marrow alone or used in conjunction with autograft, allograft/demineralized bone matrix (DBM), or synthetic materials can influence new bone formation.⁵⁻⁸ When BMA is combined with graft material, bone remodeling is enhanced and is shown, in some cases, to be equivalent to results obtained from using autograft alone.^{6,9} This graft combination provides the surgical site with the scaffold, cells, and signals necessary for successful bone healing without harvest site morbidity^{2,10} and the time-consuming steps associated with harvesting iliac crest autograft. Furthermore, bone quality and availability concerns can hamper the surgeon’s ability to use autograft in many cases.

Preparation

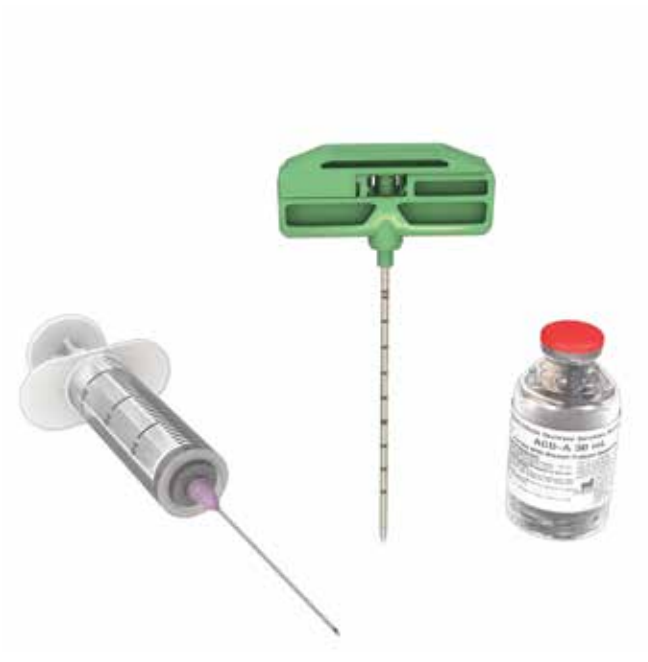

Figure 2



Figure 3

Materials

Bone marrow aspiration requires the following items:

- Scalpel (#15 blade works well)
- Mallet
- 30 ml syringe(s)
- Trocar needle and BMA cannula
- ACD-A (anticoagulant)

ⓘ **Note:** There are many types of BMA needles/cannulas on the market. In this technique, the Biomet BOS Bone Marrow Aspiration Kit (part no. 800-0705) is used for illustrative purposes.

Prime with ACD-A (to prevent clotting)

Before the procedure, use a 30 ml syringe to draw the appropriate amount of ACD-A for the desired amount of bone marrow to be aspirated as well as any additional volume needed to prime the syringe and cannula (Figure 2). For aspirating bone marrow, ensure a 1:5 ratio of ACD-A to bone marrow.

Steps

- Detach and remove the trocar needle from the BMA cannula (Figure 3)
- Attach the syringe filled with ACD-A to the cannula handle
- Depress the syringe to allow ACD-A to flow through the cannula leaving enough for a 1:5 ratio of ACD-A to bone marrow
- Attach the syringe filled with ACD-A to the cannula handle

Bone Marrow Aspiration Techniques

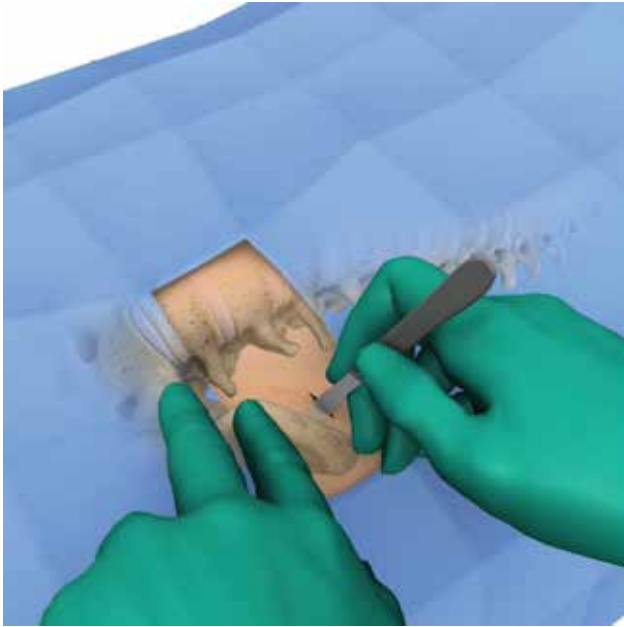


Figure 4

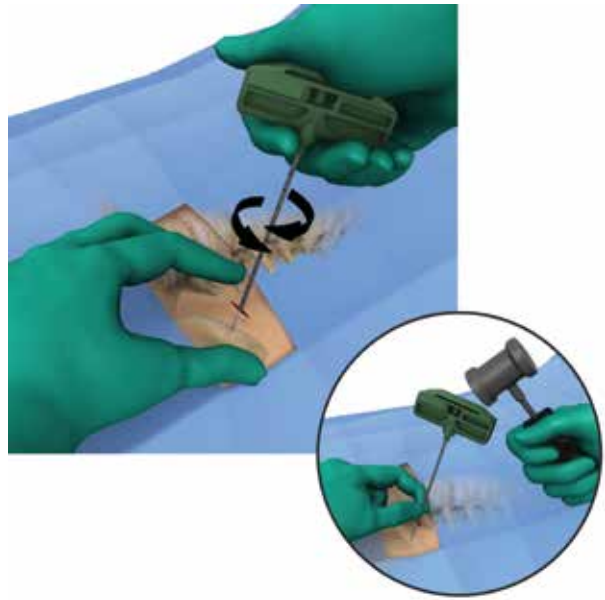


Figure 5

Anterior Iliac Crest

The donor site should be prepped and draped in a standard fashion. Prior to prepping, the site is usually blocked with 5–10 ml of local anesthetic of 0.5% buprenorphine and 2% lidocaine hydrochloride. This block helps to confirm location of the anterior iliac crest bone by direct contact of the needle with bone.

Use a standard surgical towel to make a drape by cutting a circular hole in the middle and then lay it over the anterior iliac crest. The long surgical drape can be placed over the extremity and then advanced over the crest, take care not to drag it over unprepped skin. Using a pair of scissors, cut a small hole in the surgical drape over the crest. This is usually done within the area over the surgical towel. Use a plastic adhesive tape over the drape to secure it to the skin.

A small stab incision, usually half the length of a #15 blade, is made in the skin, and the trocar needle and cannula assembly are then introduced and advanced into the anterior iliac crest, approximately 4–5 cm posterior to the medial border of the crest (Figure 4). This helps to avoid the lateral femoral cutaneous nerve, which is close to the anterior superior iliac crest.

Feel the front and back of the crest with the trocar needle point and choose a midpoint. While holding the trocar assembly in the palm, use gentle but firm pressure to advance the needle, rotating it in an alternating clockwise/counter clockwise motion until it advances between the cortices of the iliac crest. Sharp taps to the handle with the mallet will usually advance the needle easily between the walls of the iliac crest (Figure 5). In general, advance the trocar no more than 5–7 cm.

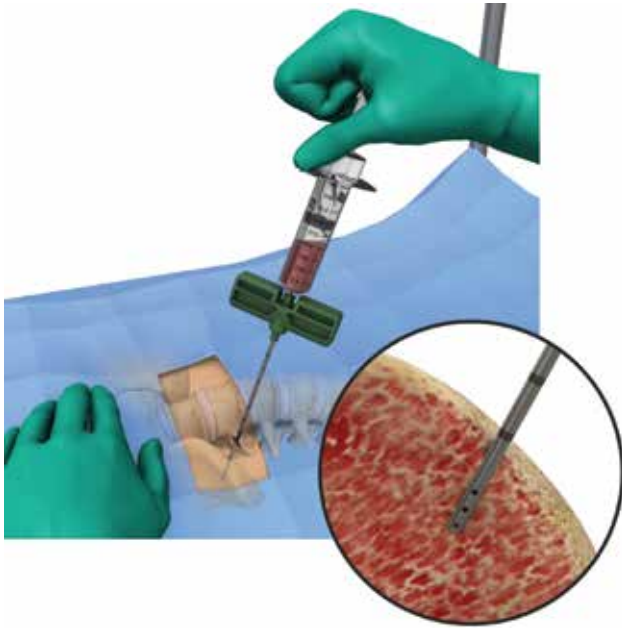


Figure 6

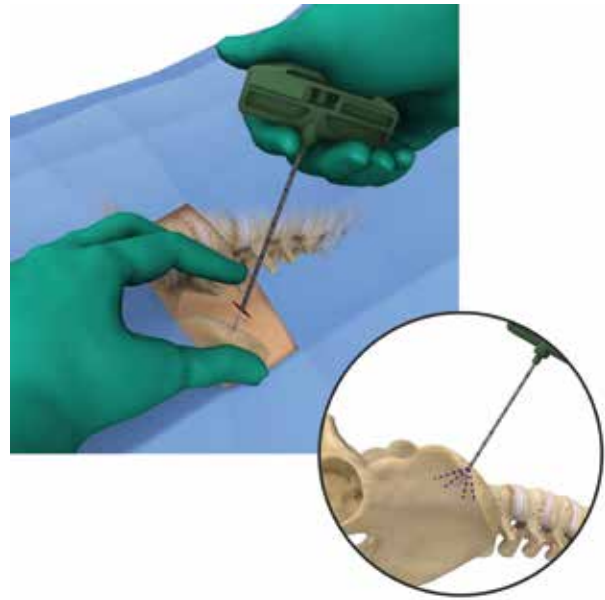


Figure 7

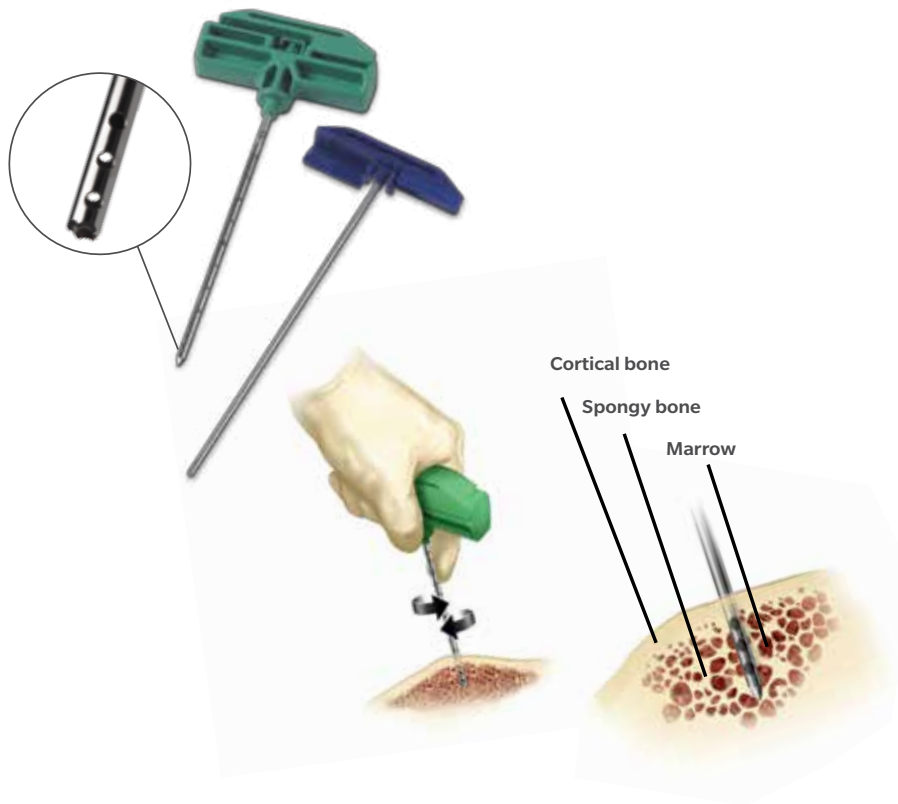
Anterior Iliac Crest (Cont.)

Once advanced into bone, leave the cannula in place; remove trocar needle, and attach the syringe with ACD-A to the top of the cannula handle (Figure 6). Ensure the distal holes of the cannula are buried within the cancellous bone. Pull back on the syringe plunger to aspirate 5–10 ml of bone marrow.

Next, detach the syringe from the cannula handle. Shake the syringe gently in an oscillating fashion to ensure the bone marrow and ACD-A are thoroughly mixed. For additional bone marrow, reattach the trocar needle onto the cannula, pull the assembly back to the surface of the iliac crest, and redirect the needle within the iliac crest (Figure 7). Continue to use the same hole initially created or create a new hole within the walls of the iliac crest approximately 10 cm away from the initial hole.

To avoid any risk of perforating the iliac crest wall, especially if the bone is osteoporotic, the surgeon may replace the trocar needle with the blunt tip stylet with blue handle as shown in Figure 8. This will ease movement of the cannula within the bone marrow cavity.

Bone Marrow Aspiration Techniques (Cont.)



Anterior Iliac Crest (cont.)

ⓘ **Note:** Approximately 50–60 ml of bone marrow may be harvested from the iliac crest fairly easily by this method with only one skin incision created above the iliac crest.

Apply local pressure to the harvest site and close the incision with one simple suture using a 4–0 absorbable suture. A small bandage may be adequate for dressing. Some patients may experience moderate pain for a couple of days but many find the process relatively pain free.

Additional Surgical Technique Tips

Obese patients may present a slight challenge due to the distance to the iliac crest. A small pillow beneath the ipsilateral hip may help to facilitate a medial drift of the abdominal pannus and often uncovers the anterior crest. Additionally, the needle on the local anesthetic syringe may be utilized to help locate the iliac crest and its margins. If there is excessive abdominal soft tissue mass, then the surgeon may want to consider harvesting from an alternative site. Bone marrow harvesting site options are presented in the next section.

The volume of bone marrow aspirated from a site can significantly affect the quality of the marrow. As a general rule, do not aspirate more than 10–12 ml of bone marrow from one insertion of the trocar needle and cannula assembly. Larger volumes of bone marrow result in excessive dilution with peripheral blood.

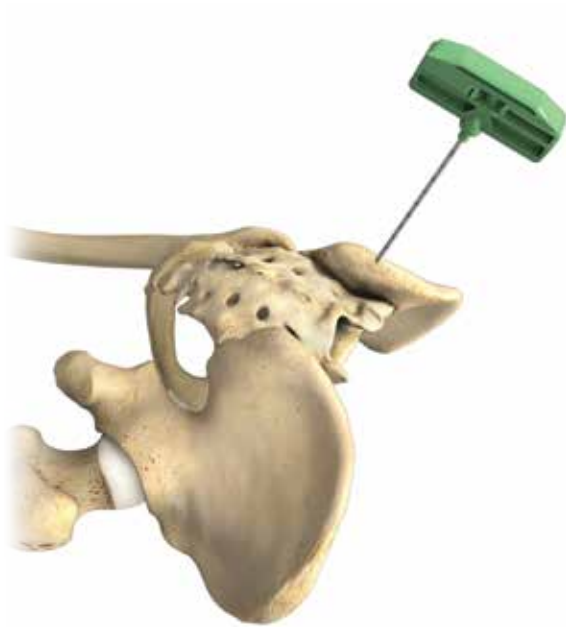


Figure 9

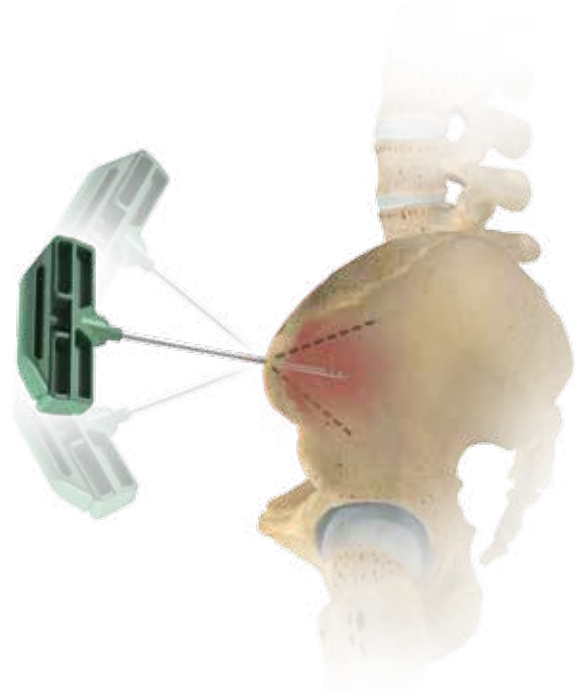


Figure 10

Additional Surgical Technique Tips (cont.)

Occasionally, it may be difficult to aspirate an adequate quantity of bone marrow from elderly patients with osteoporosis. Additionally, the risk of perforating the iliac wall increases with these patients. Alternate bone grafting options may be explored for these cases.

Posterior Iliac Crest

For the posterior iliac crest and other anatomic locations covered subsequently, excluding location-specific detail, all aspects of the bone marrow aspiration technique are identical to those described in the preceding section.

The posterior iliac crest offers a rich source of bone marrow and is readily accessible in spine surgery or other procedures utilizing a prone position. Probe the medial and lateral edges of the iliac crest and dock the trocar assembly in the middle of the superficial cortex (Figure 9). Aim the trocar 30° lateral from the para-sagittal plane and 20–30° inferior from the transverse plane. Avoid going too far laterally to avoid risk of injury to the cluneal nerves. The exact depth of optimal advancement varies somewhat, but generally, the trocar should not be advanced more than 5–7 cm.

As in the anterior approach covered earlier, redirection of the needle and cannula construct allows for additional harvesting of bone marrow (Figure 10).

Bone Marrow Aspiration

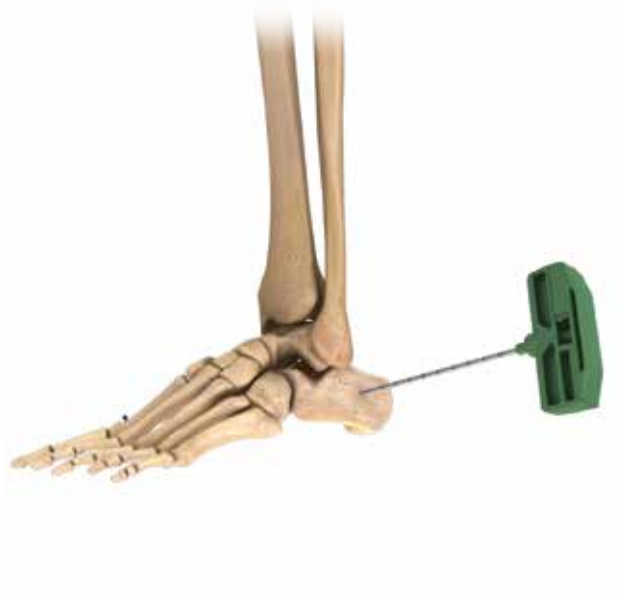

Figure 11

Calcaneus

Locate the incision above the postero-lateral wall of the calcaneus, below the sural nerve and approximately one cm anterior to the achilles tendon insertion (Figure 11). To aspirate bone marrow, several passes may be made through the calcaneus using the trocar needle and BMA cannula assembly; however, limit the number to three passes through the same insertion hole. Do not use a tourniquet during the aspiration process as it will severely limit the volume of bone marrow aspirated. Position the needle at a maximum depth within the cancellous bone to ensure all distal holes of the cannula are buried within the bone marrow.

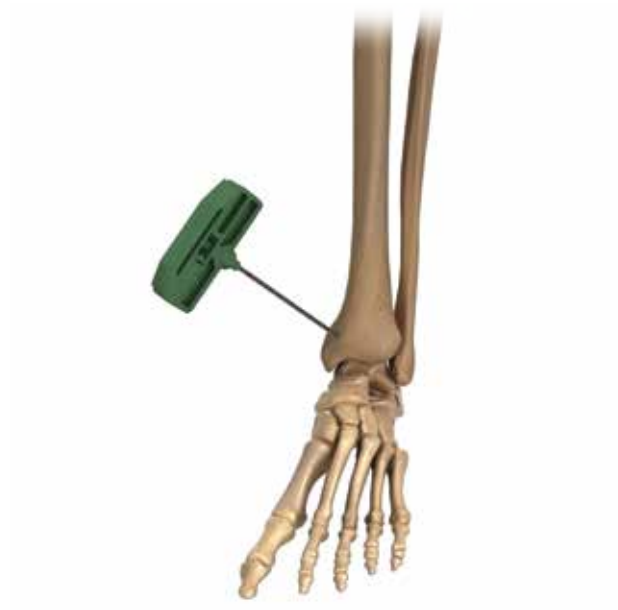

Figure 12

Distal Tibia

Locate the medial incision anterior to the posterior tibial tendon to avoid potential tendon or nerve injury (Figure 12). Antero-medially, stay a safe distance away from the saphenous nerve which lies next to the long saphenous vein. The large surface area of the distal tibia provides various points for insertion of the trocar needle and BMA cannula assembly. The needle may also be redirected in multiple directions for additional bone marrow harvest sites.



Figure 13

Proximal Tibia

Insert the trocar needle and BMA cannula assembly either through the antero-medial or antero-lateral wall of the proximal tibia (Figure 13). If utilizing an antero-lateral insertion point, note that the needle will go through additional muscle structures prior to hitting the cortex. Due to the triangular contour of the proximal tibia, to maintain a right angle to the bony surface, direct the needle in a slight oblique fashion. The large surface area of the proximal tibia also provides various points for insertion for the trocar needle. For additional bone marrow harvest sites, redirect the needle in multiple directions.



Figure 14

Proximal Humerus

Bone marrow from the proximal humerus can be harvested during arthroscopic shoulder surgery. Determine the trocar needle insertion point arthroscopically. Typically, the insertion point is adjacent to the humeral head cartilage and in the proximity of the suture anchors utilized for soft tissue repair (Figure 14). During arthroscopic surgery, introduce the trocar needle and BMA cannula assembly through the standard portal. To avoid aspirating irrigation fluid, ensure that the irrigation fluid is turned off and the distal holes of the cannula are buried well within the cancellous structure.

Appendix A Bone Grafting Applications

BMA combined with bone graft materials, such as autograft or allograft/DBM or synthetic bone substitutes, may be used in a variety of orthopedic bone grafting applications. Figures 15–24 illustrate examples of clinical applications for the use of BMA in bone grafting.

Foot and Ankle

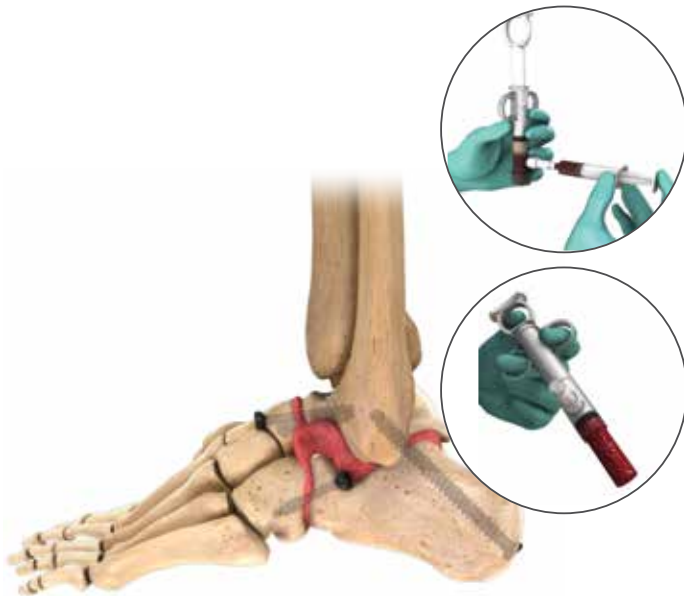


Figure 15
Triple Arthrodeses

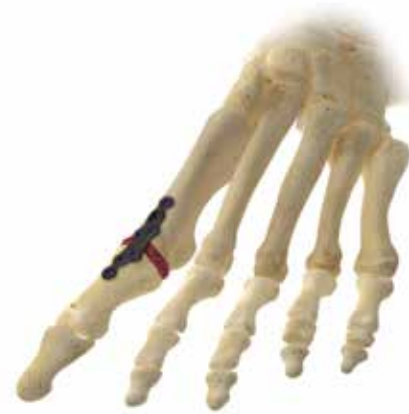

Figure 16
First Metatarsophalangeal (MTP) Joint Fusion

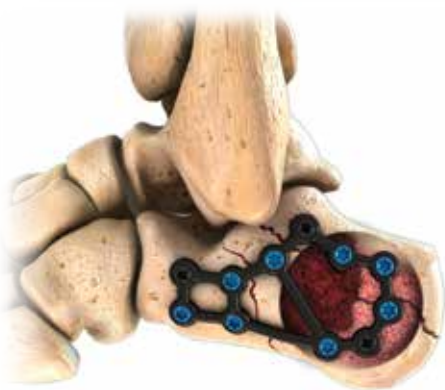

Figure 17
Calcaneal Fracture

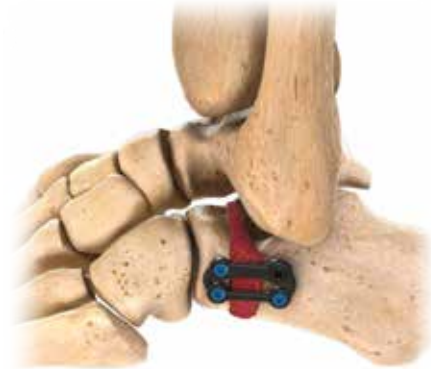

Figure 18
Foot Deformity Correction

Spine

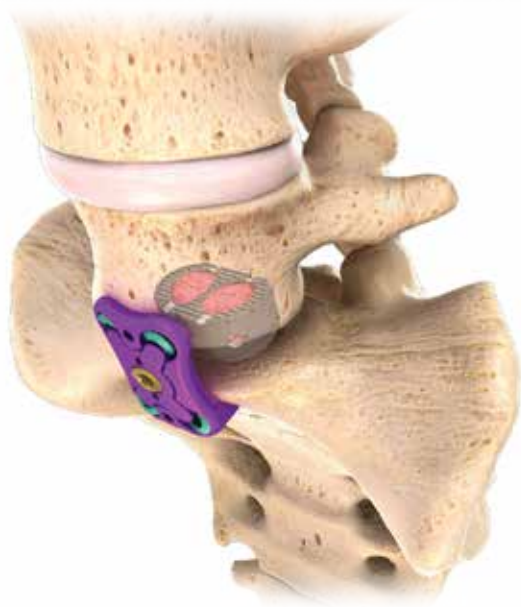

Figure 19
Spinal Fusion¹²
(using Intervertebral Cage Device)

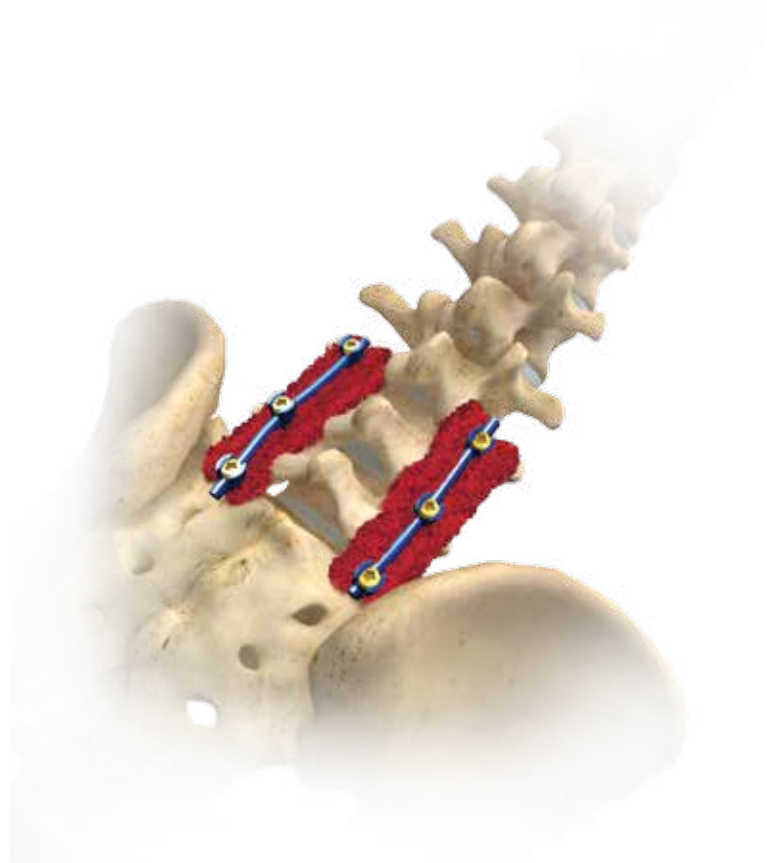


Figure 20
Spinal Fusion¹²
(Rods and Screws)

Appendix A Bone Grafting Applications (Cont.)

Lower Extremity

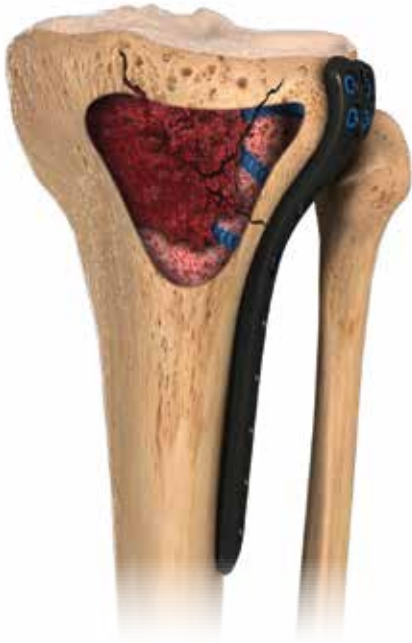

Figure 21
Proximal Tibial Fracture

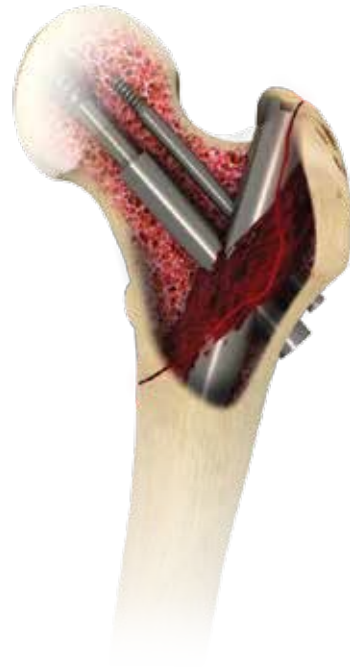

Figure 22
Hip Fracture

Revision Hip Reconstruction

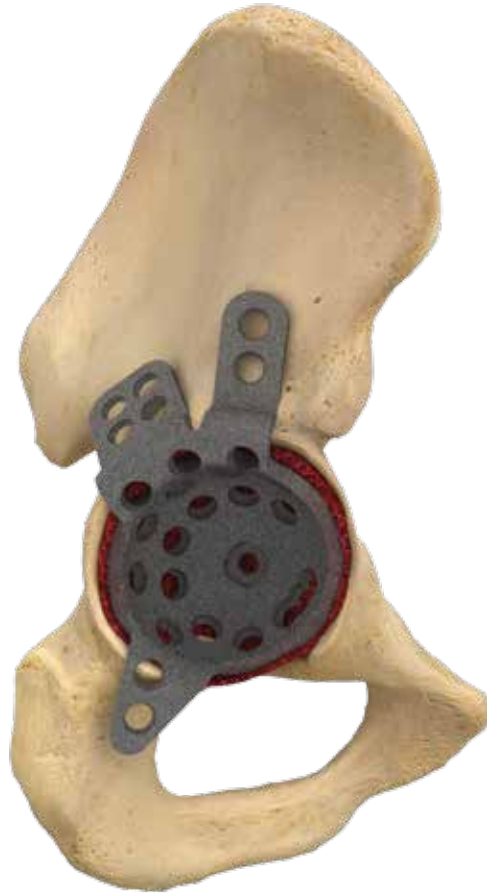

Figure 23
Acetabular Revision

Appendix A Bone Grafting Applications (Cont.)

Other

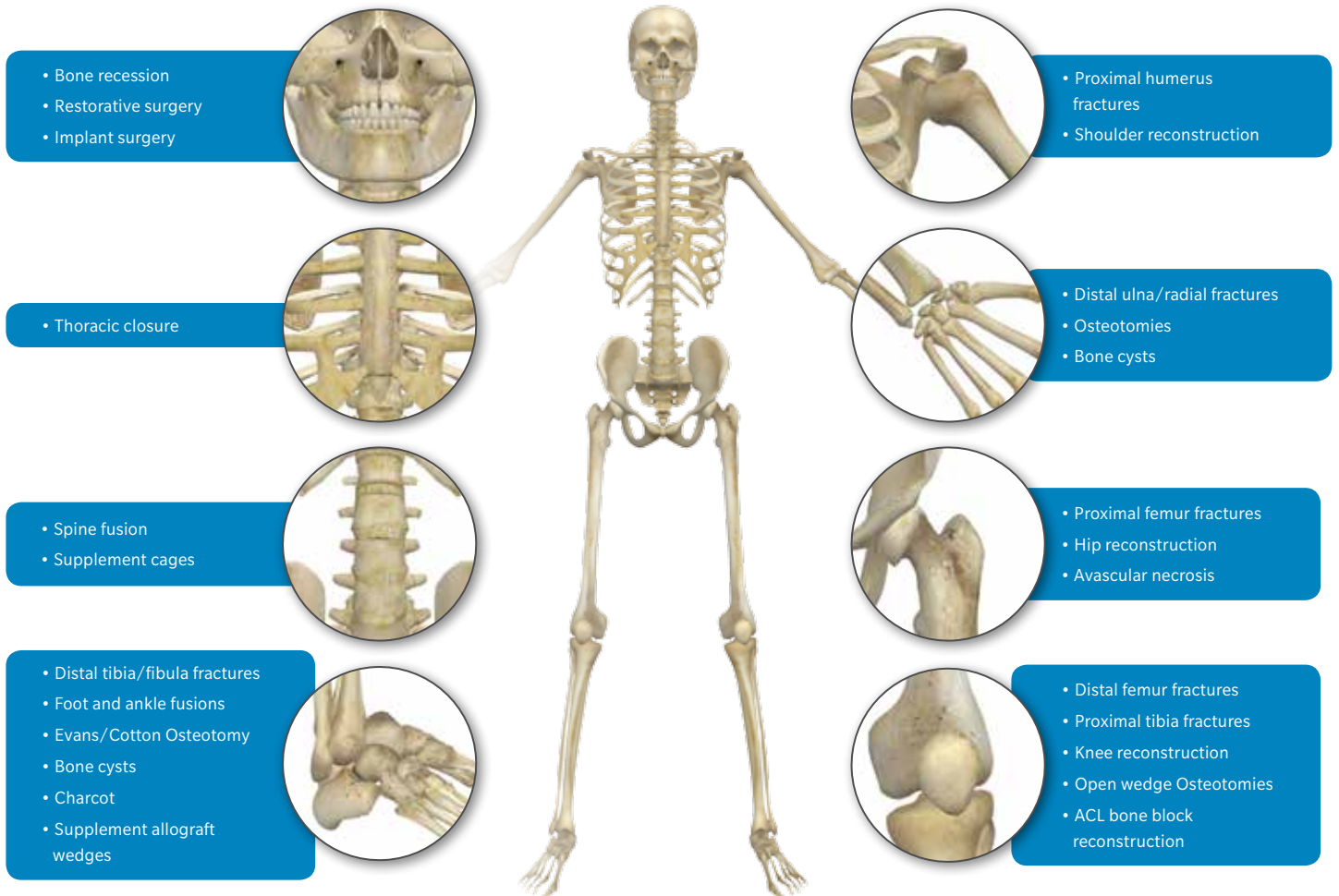










Figure 24
Other Bone Grafting Examples

Bone Marrow Aspiration Needle and Accessories

| Product | Description | Part Number |
|---|------------------------------|-------------|
|  | CDO - Curved Delivery Option | 800-0526 |
|  | Graft Preparation System | 800-0300 |
|  | BOS Bone Marrow Asp Kit | 800-0705 |

Appendix B Product Catalog Numbers

Bone Graft Products

| Product | Description | Part Number |
|--|--|-------------|
|  | Bonus CC Matrix – 5cc | 48-1805 |
|  | Bonus CC Matrix – 10cc | 48-1810 |
|  | StaGraft Cancellous DBM - 20 x 30 x 5 mm Strip | 92-3230 |
|  | StaGraft Cancellous DBM - 20 x 50 x 5 mm Strip | 92-3250 |
|  | StaGraft Cancellous DBM – 14 mm Cube | 92-3214 |

Appendix C Contraindications for Bone Marrow Harvesting

Patient factors to consider for harvesting bone marrow include active infection at the harvest site and severe bone marrow diseases such as leukemias, lymphomas, and myelodysplastic syndromes. Other contraindications may include anemia and severe osteoporosis, where the harvest might be less than optimal.

Contraindications specific to the Biomet BOS Bone Marrow Aspiration Kit are noted below:

For use only for bone marrow aspiration as determined by a licensed physician. The device is intended to be used by a physician familiar with the possible side effects, typical findings, limitations, indications and contraindications of bone marrow aspiration. The procedure should be performed on patients that are suitable for such procedure only.

Caution: For single patient use only. Do not attempt to clean or resterilize this product. After use, this product may be a potential biohazard. Handle in a manner which will prevent accidental puncture. Dispose in accordance with applicable laws and regulations. Carefully place the used needle in a sharps biohazard container after the procedure is completed.

Note: These instructions are NOT meant to define or suggest any medical or surgical technique. The individual practitioner is responsible for the proper procedure and techniques to be used with this device.

References

1. Connolly J. Clinical use of marrow osteoprogenitor cells to stimulate osteogenesis. *Clinical orthopaedics and related research number 355s*. pp s257–s266. 1998.
2. Fitzgibbons TC, Hawks MA, McMullen ST, Inda DJ. Bone grafting in surgery about the foot and ankle: indications and techniques. *J Am Acad Orthop Surg*. 2011 Feb;19(2):112-20.
3. Connolly JF, Guse R, Tiedeman J, Dehne R. Autologous marrow injection as a substitute for operative grafting of tibial nonunions. *Clinical orthopaedic related research*. (266): 259-270. May 1991.
4. Smiler D, Soltan M. *Implant Dent*. Bone marrow aspiration: technique, grafts and reports. 15 (3): 229-235. Sept 2006.
5. Schade VL, Roukis TS. Percutaneous bone marrow aspirate and bone graft harvesting techniques in the lower extremity. *Clin Podiatr Med Surg*. 2008 Oct;25(4):733-42.
6. Block, J.E. The role and effectiveness of bone marrow in osseous regeneration. *Medical Hypotheses*. 65(4): 740–7, 2005.
7. McLain, R.F., Fleming, J.E., Boehm, C.A., Muschler, G.F. Aspiration of osteoprogenitor cells for augmenting spinal fusion: Comparison of progenitor cell concentrations from the vertebral body and iliac crest. *Journal of Bone and Joint Surgery*. 87(12): 2655–2661, 2005.
8. Rougraff, B.T., Kling, T.J. Treatment of active unicameral bone cysts with percutaneous injection of demineralized bone matrix and autogenous bone marrow. *Journal of Bone and Joint Surgery (American)*. 84–A(6): 921–9, 2002.
9. Neen, D, Noyes, D, Shaw, M, Gwilym, W, Fairlie, N, Birch, N, Healos and bone marrow aspirate used for lumbar spine fusion: a case controlled study comparing healos with autograft, *Spine*, 15;31(18):E636-40, 2006.
10. Muschler, G.F., Nitto, H., Matsukura, Y., Boehm, C., Valdevit, A., Kambic, H., Davros, W., Powell, K., Easley K. Spine fusion using cell matrix composites enriched in bone marrow-derived cells. *Clinical Orthopaedics and Related Research*. 407: 102–18, 2003.
11. Muschler, G.F., Boehm, C.A., Easley K. Aspiration to obtain osteoblast progenitor cells from human bone marrow: The influence of aspiration volume. *Journal of Bone and Joint Surgery*. 79-A(11): 1699–709, 1997.
12. Theiss, S., Bone grafting technique for thoracolumbar pedicle screw and rod systems: A supplement. *Biomet Biologics, BMET1144.0*, 2015.

All content herein is protected by copyright, trademarks and other intellectual property rights, as applicable, owned by or licensed to Zimmer Biomet or its affiliates unless otherwise indicated, and must not be redistributed, duplicated or disclosed, in whole or in part, without the express written consent of Zimmer Biomet.

This material is intended for health care professionals. Distribution to any other recipient is prohibited.

For product information, including indications, contraindications, warnings, precautions, potential adverse effects and patient counselling information, see the package insert and www.zimmerbiomet.com.

©2018 Zimmer Biomet.



ZIMMER BIOMET
Your progress. Our promise.™



Legal Manufacturer
Biomet Biologics
56 East Bell Drive
P.O. Box 587
Warsaw, Indiana 46581
USA