

Key Steps to Glenoid Exposure

in Total Shoulder Arthroplasty

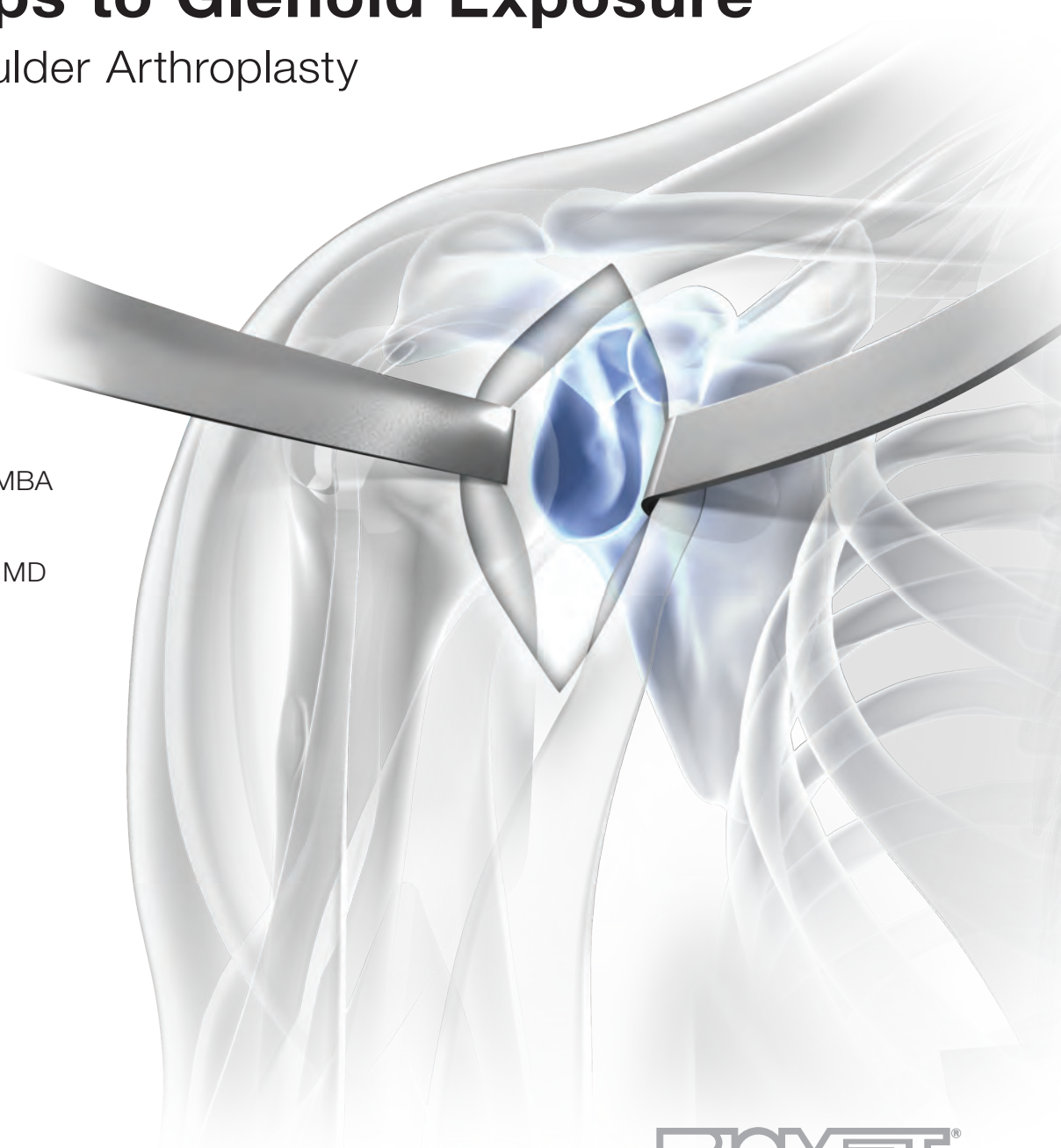
Featuring:

John Sperling, MD, MBA

Jason Hurst, MD

Quin Throckmorton, MD

Timothy Codd, MD



BIOMET[®]

One Surgeon. One Patient.®

Over 1 million times per year, Biomet helps one surgeon provide personalized care to one patient.

The science and art of medical care is to provide the right solution for each individual patient. This requires clinical mastery, a human connection between the surgeon and the patient, and the right tools for each situation.

At Biomet, we strive to view our work through the eyes of one surgeon and one patient. We treat every solution we provide as if it's meant for a family member.

Our approach to innovation creates real solutions that assist each surgeon in the delivery of durable personalized care to each patient, whether that solution requires a minimally invasive surgical technique, advanced biomaterials or a patient-matched implant.

When one surgeon connects with one patient to provide personalized care, the promise of medicine is fulfilled.

Key Steps to Glenoid Exposure

in Total Shoulder Arthroplasty

Introduction

Glenoid exposure has often been described as the most difficult part of total shoulder arthroplasty. Optimal glenoid exposure can be difficult and requires careful attention to detail.

Careful release of key soft tissue structures, removal of peripheral osteophytes on both the humerus and glenoid, appropriate humeral head cut, and key placement of specific retractors all lead to excellent glenoid visualization and access.

In this technique, advice has been combined from surgeons experienced with the Comprehensive® system, to help uncover and conquer this challenging part of the procedure.

Surgical Protocol & Photography

John Sperling, MD, MBA
Rochester, MN

DVD Content

Jason Hurst, MD
Joint Implant Surgeons
New Albany Surgical Hospital, New Albany, OH

Quin Throckmorton, MD
Campbell Clinic
University of Tennessee, Memphis, TN

Timothy Codd, MD
Johns Hopkins University
Baltimore, MD

Humeral Preparation

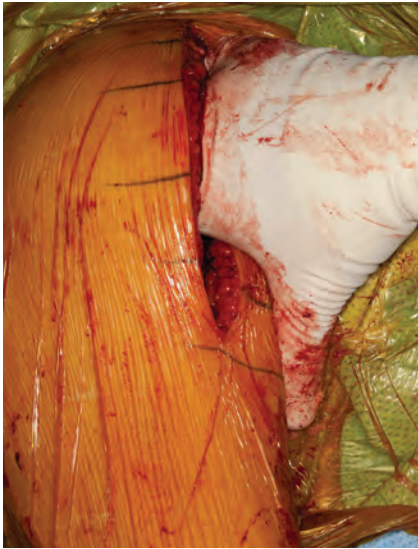


Figure 1

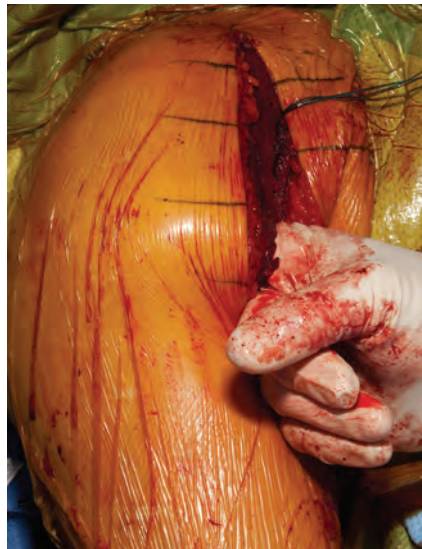

Figure 2

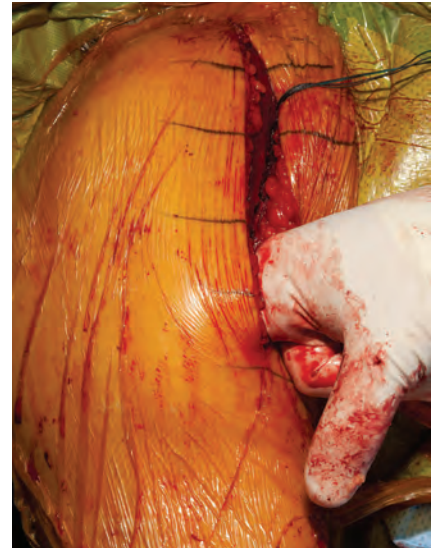

Figure 3

Deltoid Mobilization

To start, ensure the deltoid is fully mobilized proximally, and the subacromial space is cleared of any scar tissue between the deltoid and underlying rotator cuff (Figure 1).

The deltoid should be mobilized in the mid-aspect and distally. Special attention should be made to identify the axillary nerve on the undersurface of the deltoid (Figures 2 and 3).

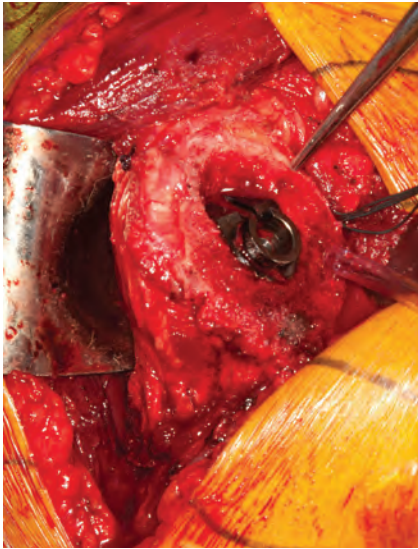


Figure 4

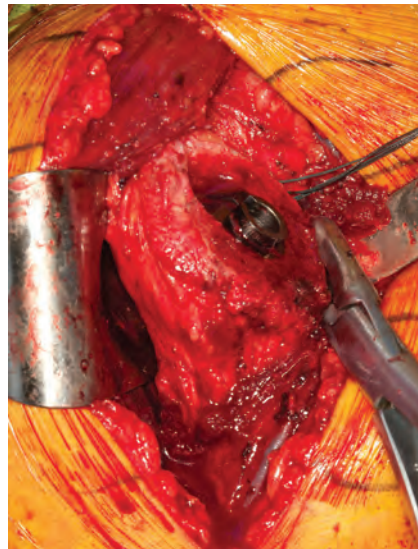


Figure 5

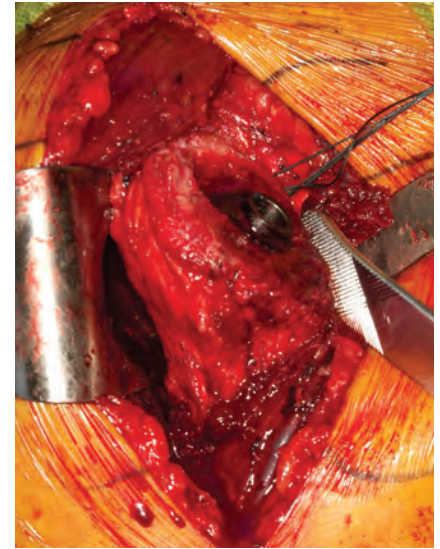


Figure 6

Humeral Head Cut

Because the humerus is funnel-shaped, a more aggressive humeral head cut can help with adequate glenoid exposure. A slightly more aggressive head cut makes the humerus narrower, which decreases the amount of bone that has to be retracted behind the glenoid. The humeral head cut should exit just above the rotator cuff insertion without violating it (Figure 4).

Inferior Capsule Release and Osteophyte Removal

With the arm placed in an adducted and externally rotated position, release the inferior capsule off the proximal humerus. Use cautery directly on the bone with progressive external rotation of the arm. Remove the humeral osteophytes to facilitate glenoid exposure (Figure 5). After osteophyte removal, a Darrach-type retractor can be used to smooth the humerus (Figure 6).

Glenoid Preparation

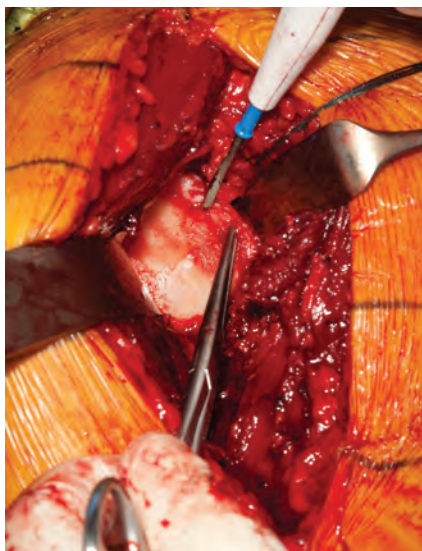

Figure 7

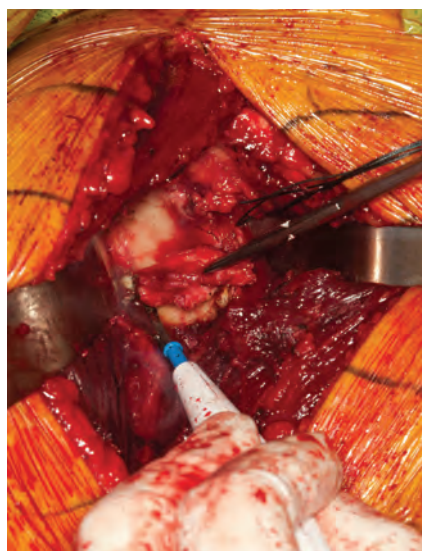


Figure 8

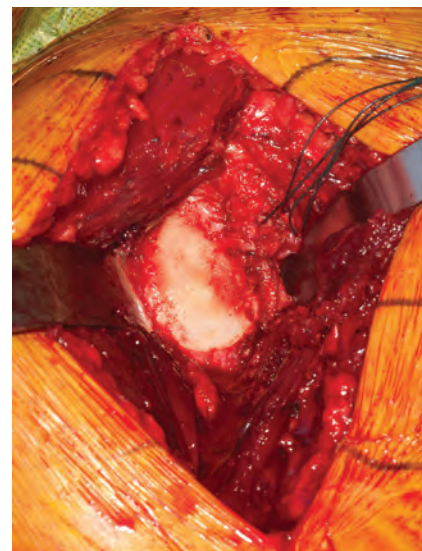


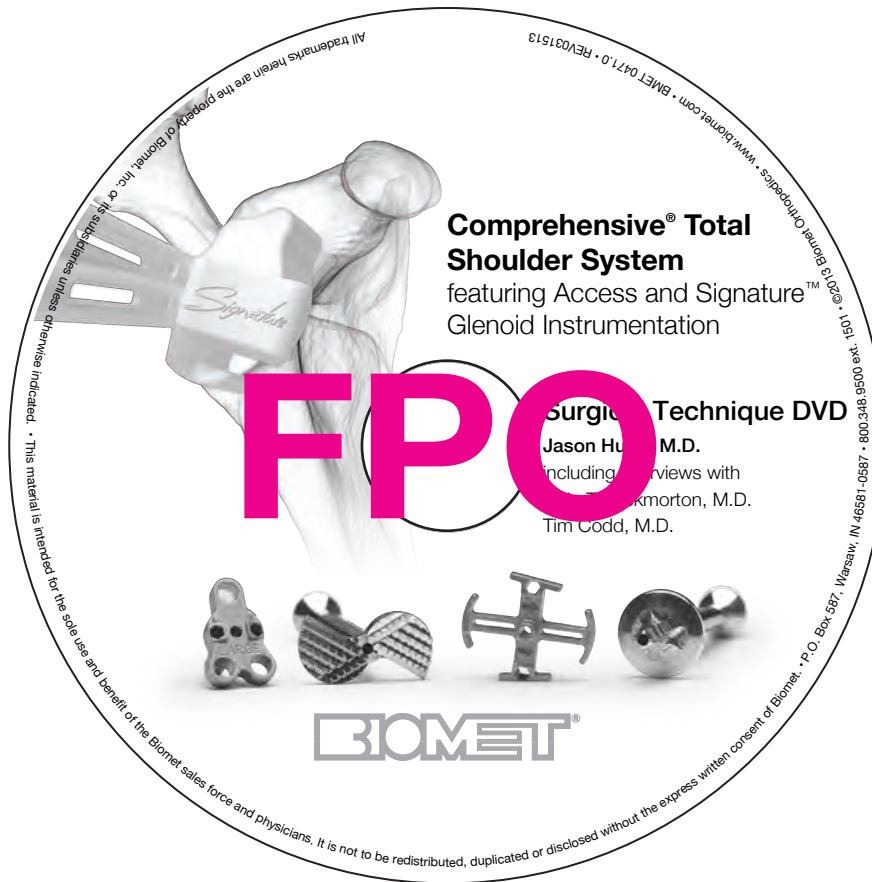Figure 9

Labral and Capsular Release

With a wide variety of retractors available for glenoid exposure, typically a wide Bhattman retractor is placed posteriorly. A Fakuda retractor is also a viable option. Split the labrum and stump of the biceps tendon at the 12 o'clock position (Figure 7). In Figure 7, a knee retractor is placed between the labrum and the subscapularis.

After removal of the anterior labrum, a thin Bhattman retractor is placed along the anterior glenoid rim. The labrum is then removed superiorly, anteriorly, and inferiorly (Figure 8). In general, the posterior labrum is also excised, but a formal posterior capsular release is not always necessary with total shoulder arthroplasty.

After the glenoid is exposed, review the CT scan to determine the wear pattern, version, and appropriate entry hole for the Steinmann pin (Figure 9).



Comprehensive® Access Instrumentation

Refer to BMET0206.0 Comprehensive® Total Shoulder System Surgical Technique for more details.

Step 1: Glenoid Sizing and Pin Insertion

Low-profile guide offers visualization for accurate placement and sizing.

Step 2: Glenoid Reaming

Low-profile, cannulated reamer enters the joint with ease.

Step 3: 2-in-1 Regenerex® Post Preparation

Ream the Hybrid® glenoid boss and Regenerex® post in one simple motion.

Step 4: Peripheral Peg Preparation

No more anti-rotation pegs. The quick-connect drill bits are designed with a magnetic connection for quick release while providing rotational stability.

Biomet, as the manufacturer of medical devices, does not practice medicine.

All trademarks herein are the property of Biomet, Inc. or its subsidiaries unless otherwise indicated.

This material is intended for the Biomet Sales force and physicians only and is NOT intended for patient distribution. It is not to be redistributed, duplicated or disclosed without the express written consent of Biomet.

For product information, including indications, contraindications, warnings, precautions and potential adverse effects, see the Comprehensive® Total Shoulder system package insert and Biomet's website.



One Surgeon. One Patient.®

Responsible Manufacturer

Biomet Orthopedics
P.O. Box 587
56 E. Bell Drive
Warsaw, Indiana 46581-0587
USA